

## WHAT IS NEUROBLASTOMA?

### ***Part 1: Description, Diagnosis and Staging***

Upon learning their child has neuroblastoma (NB), many parents feel confused, frightened, and overwhelmed. Suddenly, obscure scientific terms are being used to describe their child's situation, his or her treatment, and even the possibility of cure. The best source of information about your child's cancer is *always* his or her oncology team. However, many of us have found that some additional background information about NB makes it easier to understand this new world.

Because NB is a complex disease, we have divided this explanation into three parts: Part 1 provides general information about NB, its diagnosis, and staging; Part 2 covers the factors used to determine risk assignment, including NB tumor pathology and genetic makeup. Finally, Part 3 summarizes the risk assignment categories and how they relate to a treatment plan.

#### **Description**

##### ***Neuroblastoma is a solid tumor cancer of the sympathetic nervous system.***

Neuroblastoma is a solid tumor—a lump or mass—originating from neural crest tissue that is part of the sympathetic nervous system (SNS). This part of the nervous system is responsible for the “fight or flight” response when stress occurs. Nerves of the sympathetic nervous system run parallel along the outside of the spinal column and connect to organs. Since NB arises at the interface between the nervous system and the endocrine system (the hormone producing organs—NB is one of the few cancers that secrete hormones), it is also included in the class of neuroendocrine tumors.

The most common place for NB to originate is on the adrenal glands located above each kidney (40% of localized tumors and 60% of wide-spread disease). NB tumors can also develop in nerve tissues in the neck (1%), chest (19%), abdomen (30% non-adrenal), or pelvis (1%)—anywhere along the chain of the sympathetic nervous system.<sup>1</sup> In rare cases, no primary tumor can be discerned. See visuals of the [nervous system](#) and the [adrenal glands](#).

“Neuro-” indicates origin in nerve cells, and “blast” means immature cells. *Normal* “neuroblasts” (baby nerve cells) begin in embryonic tissue and grow and mature into functioning nerve cells. *Neuroblastoma* means the immature cells reproduce forming a mass and do not develop into functioning cells (the “-oma” ending denotes a tumor). NB is *not* a cancer of the central nervous system (CNS) and it is not a brain cancer, but occasionally NB metastasizes to the CNS. There are over 50 kinds of pediatric cancers that fall into 12 main categories, one of which is the sympathetic nervous system cancers. NB accounts for more than 97% of all sympathetic nervous system cancers.<sup>2</sup>

##### ***NB is a very rare cancer.***

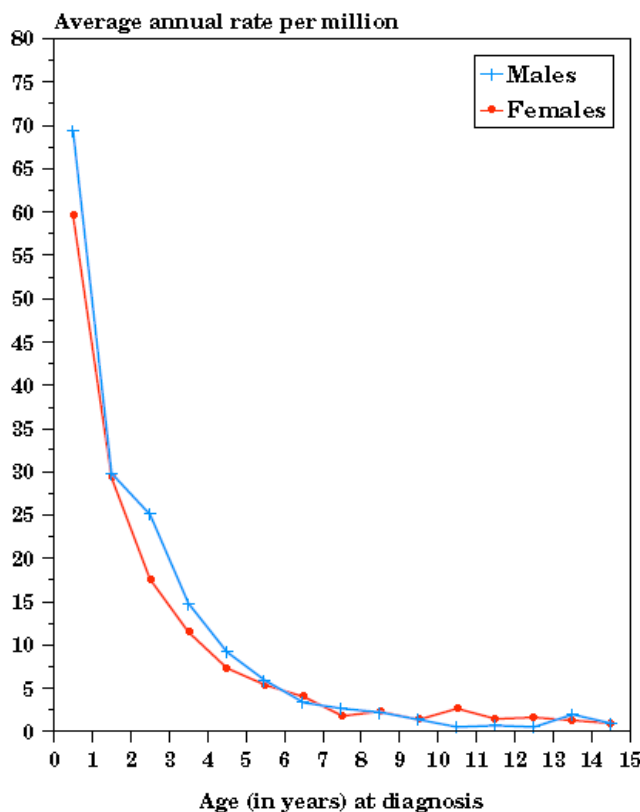
Of approximately 13,000 new cases of childhood cancer in the U.S. each year, only about 650-700 are neuroblastoma. There is similar incidence in other countries and no clear differences between ethnic groups.<sup>3</sup> About 55% of all NB patients are boys.

Understanding that NB is a rare disease is important. Many pediatric oncologists see few NB patients. You are entitled to ask how many NB patients your hospital treats, to consult with pediatric oncologists and surgeons who specialize in NB, and to get all your questions and concerns

answered to your satisfaction. **See “Questions for Your Doctors”; “U.S. NB Specialists”; and “Patients’ Rights and Responsibilities.”**

***NB is a pediatric cancer.***

Neuroblastoma generally develops in young children—half of all cancers diagnosed in infants are neuroblastomas. The median age at diagnosis is about 2 years old. Numerous children are diagnosed after age 2, but the number of diagnoses decreases as age increases. Adult diagnoses of NB account for less than 2% of all cases.<sup>4</sup> The figure below shows the relationship between age and incidence:<sup>5</sup>



**Age-specific incidence rate for sympathetic nervous system cancers (SEER)**

***No one knows the cause of NB.***

Although the cause of NB is unknown, most physicians believe it is an accidental cell growth that occurs during normal development of the sympathetic nervous system. Only 1-2% of all cases are hereditary, and a particular genetic mutation (ALK) has been implicated in most of those cases.<sup>6</sup>

***NB varies greatly in its behavior and prognosis.***

NB exhibits a wide range of behavior. Some neuroblastomas with favorable characteristics may just go away without treatment (spontaneously regress) in infants. Other neuroblastomas with unfavorable characteristics may resist very intensive multimodal treatment, and in these cases, NB is known as one of the most aggressive and difficult to cure childhood cancers. While only 4% of all childhood cancers are the high-risk form of NB, it is responsible for 15% of all pediatric cancer deaths.

More than half of NB patients have disease at diagnosis that has already spread (metastasized) to other parts of the body. The most common locations of metastases at stage 4 diagnosis are bone (66%), bone marrow (87%), lymph nodes (19%), and liver (17%); less common are lung (5%) or brain

(9%) metastases. Stage 4S include bone marrow (61%), liver (76%) and skin (12%) metastases.<sup>7</sup> NB is just one of the tumors included in the class of “peripheral neuroblastic tumors” or pNTs. Although all pNT tumors arise from the same tissue, they range in character from highly malignant NB to benign “ganglioneuroma.” Looking closely at the structure and form of the tumor under a microscope (its “pathology”), as well as determining certain genetic information inside the tumor cells, gives more information about the sub-type of neuroblastoma and its risk level (see following sections, “**Tumor Pathology and Genetics**” and “**Risk Assignment**”).

***NB differs fundamentally from adult cancers.***

NB is fundamentally different from adult cancers – it arises in different tissues, has strikingly different characteristics, and its cause is unknown. This fact is helpful to remember when well-meaning people want to share their expertise from fighting breast, colon, lung, or prostate cancer—most of their experience simply does not apply to neuroblastoma.

## **Diagnosis**

***Symptoms of NB mimic common childhood illnesses.***

Since NB is rare, most pediatricians have never seen a single case, and often the diagnosis is finally made only after a long trying period. Children may have a variety of symptoms such as irritability and low-grade fever that mimic common illnesses and viruses, or diseases such as juvenile rheumatoid arthritis that cause joint pain. Symptoms depend on where the tumor originates and if it has spread. For example, children with a tumor in the abdomen may have a swollen abdomen, constipation, vomiting, or diarrhea. A child with a tumor on the spine may stop crawling or walking, or may have weakness or paralysis. A tumor in the chest may cause breathing difficulties. A child whose disease has spread to bones may have black eyes, bone pain, bruises, fever, paleness, and may limp or stop crawling or walking. A tumor in the neck may cause different pupil size and sweating or redness on one side of the face (“Horner’s syndrome”). In very rare cases, a child has an immune response known as opsoclonus myoclonus syndrome, or OMS, causing rapid eye movements and jerky muscle motions (2% of all NB cases).

***NB can be difficult to diagnose.***

Once the pediatrician or other doctor rules out other diseases and suspects cancer, the child is referred to a pediatric oncologist to determine the diagnosis.

NB can be difficult to diagnose because it is one of several small round blue cell tumors (such as acute leukemia, Ewing’s sarcoma, Wilm’s tumor, and rhabdomyosarcoma) that look identical under a microscope. To make a diagnosis, doctors look at a variety of scans and the results of blood and urine tests, as well as biopsies from the primary tumor or other sites of disease, such as the lymph nodes or bone marrow.

A biopsy of the primary tumor is preferred because certain information about the disease can only be derived from the primary tumor before chemotherapy treatments begin. The pathologist looks at the biopsy of the primary tumor under a microscope and grades the tumor as favorable or unfavorable by the structure and form of the cells (called histology or biology). See “**Tumor Pathology and Genetics**” for more on pathology of NB cells. Biopsy samples may be a prerequisite for some treatment protocols. If a biopsy of the primary tumor is not feasible, a definite diagnosis of NB can be made from a biopsy of tissue from metastases (such as lymph nodes or bone marrow) if certain “markers” in the urine known as “catecholamines” are also elevated.

Your child’s doctor will likely want some or all of the following tests and scans:

- Urine tests

- Blood tests
- X-ray
- Ultrasound
- CT scan
- PET scan
- MRI
- Bone scan
- MIBG scan
- Bone marrow aspiration and biopsy
- **Lumbar puncture (LP) is NOT performed if NB is suspected**

These tests and scans are required to determine the location and size of the primary tumor, the extent of spread (stage), and elevated disease markers that may be present in blood or urine. Lumbar puncture may cause spread of NB into the CNS (spinal canal or brain). Additional tests are required for baseline organ function. These tests are explained in more detail in the chapter **“Getting Through Tests and Scans.”**

### Staging

The treatment a child receives for neuroblastoma is dependent on placement in a risk group. Risk is determined by age, tumor characteristics (pathology and genetics), and stage--the extent to which the disease has spread. Disease stage is determined according to the International Neuroblastoma Staging System (INSS), developed in 1988 and last revised in 1993<sup>8</sup>. The staging system is currently under revision by the International Neuroblastoma Risk Group (INRG) task force; see **Appendix** to Part 3. The diagnostic tests listed above help doctors assign the child’s disease to one of the following INSS stages (percentages of each stage are taken from North America data on 1253 NB cases<sup>9</sup>):

- **Stage 1 – 21%**  
The tumor is confined to one area of origin and can be completely removed through surgery. Although microscopic residual disease may remain after surgery, identifiable lymph nodes on both sides of the body are negative for NB.
- **Stage 2 – 15%**  
2A - The tumor is confined to one area but because of size, location, or proximity to other organs, cannot be completely removed. Identifiable lymph nodes on both sides of the body are negative for NB.  
2B - The tumor is confined to one area and may or may not be completely removed. Identifiable lymph nodes on the side of the body where the tumor is located are positive for NB, but lymph nodes on the opposite side of the body are negative for NB.
- **Stage 3 – 17%**  
The tumor crosses the midline of the body (defined as the spine) and may or may not have spread to nearby lymph nodes; OR  
the tumor is confined to one area of the body with disease in lymph nodes on the other side of the body; OR  
the tumor is located crosses the midline with disease in lymph nodes on both sides of the body
- **Stage 4 – 41%**  
Neuroblastoma is found in distant lymph nodes, bone marrow, bone, liver, or other organs (except in the special circumstances of Stage 4S, explained below). Indication of presence of NB cells by immunocytology alone (no visible tumor cells in bone marrow biopsy or aspirate) does not classify a child as stage 4.<sup>10</sup>
- **Stage 4S – 6%**  
Usually in infants, the tumor is confined to one area of the body, like a Stage 1 or 2 tumor, but disease has spread to only the liver, skin, or less than 10 percent of the bone marrow (no bone lesions).

## Summary

NB is a rare solid tumor cancer of the sympathetic nervous system. It has no known cause, primarily affects infants and young children, and is often difficult to diagnose. A variety of tests are needed to identify the disease and the extent of spread. Neuroblastoma varies greatly in its behavior and severity, and treatment is based on risk assignment, not stage. The next section, **“Tumor Pathology and Genetics,”** discusses some of the very technical scientific information used to determine risk assignment. The final section, **“Risk Assignment,”** sets forth the three risk assignment categories and their relation to treatment intensity and outcome.

## Sources:

Cheung & Cohn, eds. *Neuroblastoma*, Springer (2005)

The American Cancer Society: [Detailed Guide to Neuroblastoma](#)

Memorial Sloan-Kettering Cancer Center: [Pediatric Cancer Care—Neuroblastoma](#)

CureSearch: The National Childhood Cancer Foundation and Children’s Oncology Group--  
[Neuroblastoma](#)

eMedicine: [Neuroblastoma](#) by Norman J. Lacayo, MD and Neyessa Marina MD, Department of Pediatrics, Division of Hematology-Oncology, Stanford University and Lucile Salter Packard Children's Hospital

Please contact [info@cncfhope.org](mailto:info@cncfhope.org) with any comments

---

<sup>1</sup> Friedman GK, Castleberry RP. [Changing Trends of Research and Treatment in Infant Neuroblastoma Pediatr Blood Cancer](#) 2007;49:1060–1065

<sup>2</sup> SEER Pediatric Monograph, [Introduction](#), NCI

<sup>3</sup> Stiller CA, Parkin DM (October 1992). "International variations in the incidence of neuroblastoma". *Int. J. Cancer* 52 (4): 538–43. [PMID 1399133](#)

<sup>4</sup> Ladenstein R, Pötschger U, Hartman O, *et al.* (June 2008). "[28 years of high-dose therapy and SCT for neuroblastoma in Europe: lessons from more than 4000 procedures](#)". *Bone Marrow Transplant.* 41 Suppl 2: S118–27. [PMID 18545256](#).

<sup>5</sup> [Sympathetic Nervous System Tumors](#), SEER

<sup>6</sup> Mossé YP, Laudenslager M, Longo L, *et al.* (October 2008). [Identification of ALK as a major familial neuroblastoma predisposition gene](#). *Nature* 455 (7215): 930–5. [PMID 18724359](#).

<sup>7</sup> Cheung & Cohn, *Neuroblastoma*, Springer (2005), p. 70

<sup>8</sup> Cheung & Cohn, *Neuroblastoma*, Springer (2005), p. 151

<sup>9</sup> Cheung & Cohn, *Neuroblastoma*, Springer (2005), p. 74

<sup>10</sup> Cheung & Cohn, *Neuroblastoma*, Springer (2005), p. 71